



The Work-Up

Diagnostic Services Unit | Issue 4 - November/December, 2022

Inside this Issue

Spotlight: Anatomic Pathology

Mycoplasma hyorhinis in pigs

Acute hemorrhagic diarrhea syndrome in a dog

Johne's disease in bison

Endocarditis in a horse

Thin ewe syndrom

Necrotic enteritis in turkeys

Tips & Tricks: shipping swabs for bacteriology

DSU Announcements

Please ensure samples shipped to the DSU are not scheduled to arrive on weekends or holidays.

Holiday closures:

Remembrance Day:
Friday, November 11, 2022

Christmas & New Years*:
December 24, 2022 to January 1, 2023

*The last days the DSU will accept samples before the Christmas break are:

Bacteriology: Tuesday, December 20, 2022

Surgical biopsies & field necropsies:
Thursday, December 22, 2022

Necropsy: noon on Friday, December 23, 2022

SPOTLIGHT

Anatomic pathology uses macroscopic and microscopic examination of tissues, organs, and whole bodies to diagnose disease. The anatomic pathology service at the DSU opened in 2010, largely to support teaching and research at UCV. Its scope has grown considerably over the years, and now provides services to veterinarians across Alberta. Anatomic pathology services at the DSU include necropsy, examination of tissues from field necropsies, and surgical pathology. The DSU has 8 anatomic pathologists on rotating diagnostic duty including individuals with specialization in poultry and wildlife pathology. Along with diagnostic duty, the anatomic pathologists play an important role in undergraduate and graduate teaching and research at UCV. Alongside the pathologists are 3 necropsy technicians assisting with diagnostic cases and teaching.



Mycoplasma hyorhinis causes polyserositis and arthritis, typically in 3-10 week old (weanling) piglets. A commensal bacteria of the upper respiratory tract, it may also contribute to the Porcine Respiratory Disease Complex (PRDC). Acutely, clinical signs include sick pigs and fever with abdominal discomfort and increased morbidity in the barn. Affected piglets may recover but often have internal adhesions, lameness, and poor gains. On pathology, fibrinous polyserositis and arthritis are expected. This organism cannot be cultured by routine methods and PCR is required to confirm the diagnosis. Differential diagnoses include *Glasserella parasuis* and *Streptococcus suis*.

Acute hemorrhagic diarrhea syndrome (AHDS) was the suspected cause of sudden death in a 12 year old male

medium-sized dog. The dog presented on emergency with vomiting, anorexia, weakness, lethargy, and collapse. Diagnostics and symptomatic treatment were performed before the dog suddenly died. Gross necropsy findings were non-specific with diffusely dark red jejunum and ileum with bloody content and suspected bone fragments. Histopathology showed severe lesions in the small intestine typical of AHDS, including hemorrhage, fibrin thrombi in the mucosa, and inflammation. AHDS is usually a diagnosis of exclusion and primarily seen in young to middle-aged small and toy-breed dogs making the signalment unusual in this case. The etiology and pathogenesis are not definitively known. *Clostridium perfringens* was isolated from the small intestine in this case and may have contributed to the syndrome.

The Work-Up

Diagnostic Services Unit

Issue 4 - 2022

DSU Team

Anatomic Pathologists:

Dr. Jennifer Davies
Dr. Dayna Goldsmith
Dr. Ashish Gupta
Dr. Cameron Knight
Dr. Carolyn Legge
Dr. Jamie Rothenburger
Dr. Amy Warren
Dr. Erin Zachar

Clinical Pathologists:

Dr. Angelica Galezowski
Dr. Catherine Wagg
Dr. Amy Warren

Microbiologist:

Dr. Beverly Morrison

Support Staff:

Jim Carlsen
Makaela Douglas
Mai Farghaly
Karan Gadani
Lori Goodbrand
Jennifer Larios
Samantha Lewin
Heather Mitchell-Matheson
Mel Nicolas
Dr. Lindsay Rogers
Sara Skotarek Loch

DSU Contact Information

<https://vet.ucalgary.ca/DSU>

E-mail: dsu@ucalgary.ca

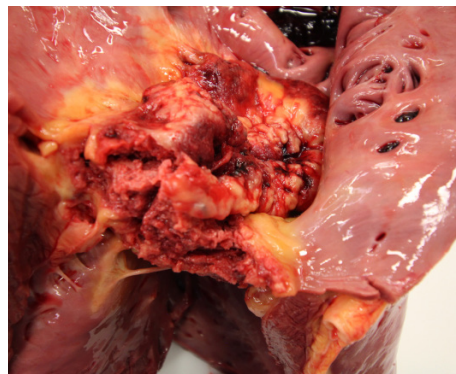
Phone: 403-220-2806

Fax: 403-239-6984

Clinical Skills Building
11877 85th Street NW
Calgary AB, T3R 1J3

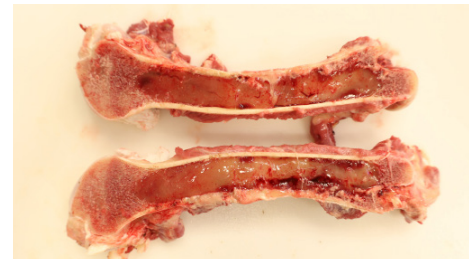Johne's disease, caused by *Mycobacterium avium* subsp. *paratuberculosis* (MAP) also causes disease in bison. A bison cow had clinical signs including wasting, dehydration, and diarrhea. Histopathology of the small intestine and mesenteric lymph nodes revealed granulomatous inflammation and acid-fast bacteria within macrophages and giant cells consistent with a diagnosis of Johne's disease. Positive PCR results for MAP confirmed the diagnosis.

Septic right atrioventricular valve endocarditis led to septic pulmonary thrombosis and congestive right sided heart failure in a 13 year old warmblood mare. The mare presented with weight loss and was treated with TMS with minimal improvement. After the course of antibiotics, she presented with fever, tachycardia, ventral and limb edema, and a jugular pulse; ascites, thoracic fluid, and an irregular tricuspid valve were seen on ultrasound. Ultrasound findings were confirmed by necropsy and histopathology with septic suppurative valvular endocarditis of the tricuspid valve and thrombi showered throughout the lungs. Lesions of chronic passive hepatic congestion were present in the liver. A sample of thoracic fluid produced *Streptococcus* spp.



Endocarditis, right AV valve

Thin ewe syndrome was the cause of weakness and death in a sheep flock following the introduction of newly purchased ewes. A classic presentation of internal caseous lymphadenitis (CL) caused by *Corynebacterium pseudotuberculosis* in sheep, it leads to abscess of internal organs, chronic weight loss, and ill thrift. These ewes also had a chronic bronchopneumonia. Peripheral CL causes abscesses in peripheral lymph nodes. CL is a chronic and contagious disease mainly of sheep and goats, but occurs sporadically in other species. It spreads through contact with purulent material from an infected animal, often through a skin injury such as from shearing. Treatment is possible but CL usually recurs. Culling infected animals from the flock is recommended. This case highlights the importance of biosecurity to the health of herds and flocks.



Serous atrophy of fat from chronic weight loss

Necrotic enteritis was the cause of increased mortality in a flock of 30 day old turkey toms. After testing negative for HPAI, the toms were submitted for necropsy. On gross necropsy they had dilated small intestines filled with chunky content, suspicious for necrotic enteritis. Histopathology findings of mucosal necrosis associated with abundant large bacilli and culture of both *Clostridium perfringens* and *Paenoclostridium sordellii* confirmed the diagnosis. Coccidial oocytes were also observed on histopathology and could have played a role in causing initial intestinal damage.

Tips & Tricks: Bacteriology

How to ship a swab for best results: The preferred swab for sampling should have dacron, rayon or nylon tips with plastic handles as cotton and wood can inhibit growth of fastidious bacteria. In most situations, submitting the swab in transport media (Amies, Stuart's) is recommended to preserve bacterial viability. Samples should be refrigerated and shipped with ice packs to the DSU as soon as possible after collection to prevent overgrowth by contaminants.

