



The Work-Up

Diagnostic Services Unit | Issue 9 - September/October, 2023

Inside this Issue

Spotlight: Dr. Erin Zachar
Scrapie in sheep and goats
Hemangiosarcoma in a Golden Retriever
Reovirus in poultry
Potomac Horse Fever in a horse
Mixed pneumonia in calves

DSU Announcements

Holiday Closures:

Labour Day: Monday, Sept. 4, 2023

National Day of Truth and Reconciliation: Monday, Oct. 2, 2023 (*potential closure - TBD by the University of Calgary Leadership. An email notice will be sent as soon as we have further information*)

Thanksgiving: Monday, Oct. 9, 2023

The DSU Cytology Service will remain closed until September 2024. Any cytology submissions will be sent out during this time.

With mixed emotions, we wish Samantha Lewin, the DSU's administrative assistant, all the best as she moves to a new Senior Administrative Assistant role within UCVM.

Wishing Makaela Douglas and Madeleine Gauthier all the best as they start the new school year!

Welcome Chloe Ingham (Ancillary Services Technician), Patrick Fuller (Necropsy Technician), and Callum MacDonald (Ancillary Services Technician) who all start at the DSU in September!

Congratulations to Ciara O'Higgins (Necropsy Technician) as she starts a new adventure on maternity leave!

SPOTLIGHT

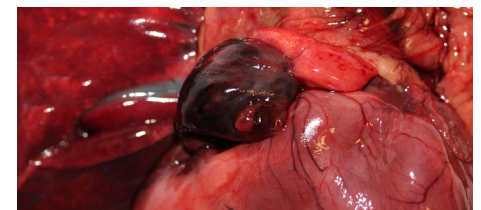
After graduating from the Western College of Veterinary Medicine (WCVM) with a DVM in 2007, Erin spent 2 years as a mixed practice veterinarian in Pincher Creek, Alberta, followed by 4 years as a companion animal veterinarian in the same practice. She finished an anatomic pathologic residency program at the WCVM in 2015 and completed a Senior Residency at the WCVM the following year. In 2017, Erin began working as a diagnostic veterinary anatomic pathologist with Prairie Diagnostic Services in Saskatoon. In 2020, Dr. Zachar joined UCVM as a Diagnostic Veterinary Anatomic Pathologist with the Diagnostic Services Unit. Erin comes from a family of veterinarians; her father practices in Pincher Creek, Alberta, and her sister in Wetaskiwin. She is happy to be back living and working in Alberta! Erin adopted a former teaching Beagle, Po, and if you are lucky he might just wake up from a nap to greet you when he is in the office.



Scrapie is a transmissible spongiform encephalopathy (TSE) causing a fatal and degenerative disease affecting the nervous system of sheep and goats. It is a federally reportable disease in Canada. Like other TSEs, scrapie develops slowly with most cases occurring in animals 2-5 years of age. Signs of scrapie in North America can vary, are non-specific, and include unexplained weight loss, trouble standing and walking, behavioural changes, general poor doing or sudden death. Animals become infected through exposure to other infected animals and scrapie-contaminated environments. A common route of transmission is through fluid and placental tissue from infected females at birthing, however other fluids such as milk, urine, feces, and saliva can also transmit the disease. Both male and female sheep and goats can become infected with, and transmit scrapie. Scrapie is diagnosed after death by detecting abnormal scrapie prions in the brain tissue and/or lymph nodes. No reliable individual live animal test exists for detecting scrapie. If you suspect an animal has scrapie or are interested in participating in complimentary surveillance testing, contact your local Cana-

dian Food Inspection Agency (CFIA) [district office](#). Click [here](#) for more information about scrapie.

A right auricular hemangiosarcoma with hemopericardium, cardiac tamponade, and pulmonary metastasis was diagnosed in a 7-year-old Golden Retriever who died suddenly following an episode of vomiting. Toxin ingestion was suspected. On necropsy, the pericardium was markedly distended with blood and a friable, red mass effaced the right auricular appendage. Numerous, dark red to black nodules (metastases) were scattered randomly in the in lungs. This was suspected to be a hemangiosarcoma given gross appearance and breed of dog. The diagnosis was confirmed on histology. Visceral hemangiosarcoma is an aggressive tumor associated with a grave prognosis. This case highlights the important use of post-mortems to sudden death investigations.



The Work-Up

Diagnostic Services Unit

Issue 9 - 2023

DSU Team

Anatomic Pathologists:

Dr. Jennifer Davies
Dr. Dayna Goldsmith
Dr. Ashish Gupta
Dr. Cameron Knight
Dr. Carolyn Legge
Dr. Jamie Rothenburger (*on leave*)
Dr. Amy Warren
Dr. Katie Waive
Dr. Erin Zachar

Clinical Pathologists:

Dr. Angelica Galezowski
Dr. Catherine Wagg
Dr. Amy Warren

Microbiologist:

Dr. Beverly Morrison

Support Staff:

Jim Carlsen
Dr. Manga Devi
Mai Farghaly
Patrick Fuller
Karan Gadani
Lori Goodbrand
Chloe Ingham
Jennifer Larios
Samantha Lewin
Callum MacDonald
Mel Nicolas
Ciara O'Higgins (*on leave*)
Dr. Lindsay Rogers
Sara Skotarek Loch

DSU Contact Information

<https://vet.ucalgary.ca/DSU>

E-mail: dsu@ucalgary.ca

Phone: 403-220-2806

Clinical Skills Building
11877 85th Street NW
Calgary AB, T3R 1J3

Avian reovirus has been increasingly diagnosed in poultry submissions to the DSU. It typically causes viral arthritis/tenosynovitis in young broilers and commercial turkeys, and sometimes runting-stunting syndrome, a multifactorial disease. In older broiler breeders and turkeys, tendon rupture and hemorrhage are commonly seen. Recently in the US and in Canada, new strains of avian reovirus are causing encephalitis in turkeys. Common clinical signs include lameness, swelling of the hock, and stunting. Diarrhea and loss of color in the legs and beak may also occur. Neurological signs may include incoordination, tremors, twisted necks, or twitching. Mortality is typically low, but morbidity can be high. Presumptive diagnosis is by clinical signs and histopathology with confirmation by PCR. Ideal samples for reovirus testing include affected tendons, heart, and brain if neurological signs are present. Cecal tonsils are not preferred because enteric reovirus are common inhabitant of poultry. Other causes of lameness must also be ruled out. The disease often transmits vertically, and parent flock vaccination is an important preventative strategy. New strains are occasionally identified and need to be incorporated into vaccines to ensure ongoing efficacy.



Neurological signs in a turkey from reovirus

(PC: Dr. Hayley Bowling)

Potomac Horse Fever (PHF) was diagnosed in a 7-year-old mare submitted for necropsy following acute fever, watery diarrhea, depression, incoordination, and death occurring in late summer. Gross necropsy confirmed non-specific watery diarrhea with *Salmonella*, *Clostridium difficile*, and PHF as the main differentials. Histopathology was unrewarding due to autolysis of the tissues. An Equine Diarrheal PCR Panel was negative for the common causes of equine diarrhea including *Neorickettsia risticii*, *Salmonella*, and *Clostridium difficile*. An additional sample was sent for PCR for a novel agent causing PHF, *Neorickettsia findlayensis*. This PCR was positive for *N. findlayensis*. This case highlights an emerging cause of PHF in Alberta and the importance of ongoing development of diagnostic tests for novel agents causing common diseases.

A primary viral bronchointerstitial pneumonia caused by BRSV was diagnosed in 2.5-month-old Jersey calves with a history of respiratory disease progressing to extreme dyspnea and hemoptysis. The necropsy was performed in the field and tissues were submitted for histopathology and ancillary diagnostics. Histopathology showed severe lung pathology with two patterns: bronchointerstitial pneumonia and bacterial bronchopneumonia. Fresh tissue submitted was too autolyzed for culture and was submitted for PCR of respiratory pathogens instead. The PCR was positive for Bovine Respiratory Syncytial Virus (BRSV), the cause of the primary viral bronchointerstitial pneumonia and *Mycoplasma bovis* and *Pasteurella multocida*, the causes of the secondary bacterial pneumonia.

Tips & Tricks

Have a case of suspected polioencephalomalacia in a ruminant? Have a Wood's lamp in your clinic? Remember that cerebrocortical autofluorescence under ultraviolet light can provide a quick and presumptive diagnosis of PEM. However, not all cases of PEM will show autofluorescence, so its absence does not exclude PEM. Always send the brain to the lab to look for histologic lesions to confirm the diagnosis.

